


Elliot Health System

One Elliot Way
Manchester, NH 03103
www.elliotohospital.org


Elliot Orthopaedic Surgery Specialists

A Department of Elliot Hospital

185 Queen City Ave.
Manchester, NH 03101
(phone) 603-625-1655
(fax) 603-626-4686

June 17, 2016


Name: 




W/C Claim #: 


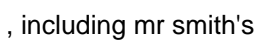

Doctor/PA-C/APRN: Paul Scibetta, MD

Diagnosis: left Quadriceps Tendon tear

To Whom It May Concern:

Please allow this letter to serve as a detailed report of events concerning your client and our patient Mr. 

 was evaluated in the Elliot Hospital Emergency room on April 23, 2016 for injury to his left lower extremity. Following this visit he was referred to Occupation Health for further treatment and care. On April 26, 2016  was seen in Occupation Health and sent for U/S of the left thigh followed by MRI, both of these test resulted positive for quadriceps tear therefore Mr.  was referred here to Orthopaedics.

On May 2, 2016 Mr.  was evaluated by me and all records , including mr smith's narrative of his daily duties as a letter carrier, along with test results were reviewed. On examination Mr.  was to have tenderness with palpation at the proximal

June 17, 2016
[REDACTED]

Page 2.

pole of the patella and any palpation of his quad tendon. When asked to do a straight leg raise maneuver this is very painful. With passive flexion to the knee, he is able to extend it but it is very painful and weak. Review of MRI shows complete rupture of the rectus femoris portion of the quadriceps tendon with retraction of 1.cm.


The diagnosis for this patient is a quadriceps tendon tear (ICD 10: S76.112a). My recommendation is surgical intervention for repair of the left quadriceps tendon tear.

Mr. [REDACTED] underwent surgery for repair of his quad tendon tear on May 4, 2016. Post surgical appointment have been as follows; 5/17/16, 5/31/16, 6/16/16. Currently the next follow up visit is scheduled for 7/14/16.

It is my medical opinion that Mr. [REDACTED]'s left quadriceps tendon tear is directly related to the described work injury which occurred on April 23, 2016 wherein Mr. [REDACTED] fell at work while delivering mail.

I hope you find this information helpful to you. Please do not hesitate to contact my office with further questions or concerns.

Sincerely,


Paul Scibetta Jr., D.O.